J. Appl. Environ. Biol. Sci., 7(2)163-170, 2017

ISSN: 2090-4274
Journal of Applied Environmental and Biological Sciences
www.textroad.com

Discrimination of Normal and Pathological Brain MRI Using Color Moments and Random Subspace Ensemble Classifier

[a*]Fazli Wahid, [a]Rozaida Ghazali, [b]Muhammad Fayaz, [b]Abdul Salam Shah, [c]Habib Shah

[a]Universiti Tun Hussein Onn Malaysia
[b]Shaheed Zulfikar Ali Bhutto Institute of Science and Technology, Pakistan
[c]College of Computer Science, King Khalid University, Abha, Saudi Arabia

Received: August 20, 2016
Accepted: December 1, 2016

ABSTRACT

The vital role of medical imaging in the automatic and efficient diagnosis and treatment in a short frame of time cannot be ignored. There are many imaging techniques for the diagnostic purpose of the human brain with each technique having its own advantages and disadvantages. One of the most important imaging modalities for diagnosis and treatment of brain diseases is Magnetic Resonance Imaging (MRI). In our work, we have used MRI for the classification of the brain into normal or abnormal due to its capability of going into much finer details of the brain's soft tissues. With the advancement of technologies, new algorithms and techniques are developed for automatic discrimination of the normal human brain from abnormal. In this paper, Random Subspace (RS) ensemble classifier that uses K-Nearest Neighbors as base classifier has been used to classify the human brain MRI into normal and abnormal. Total of nine features are extracted from the red, green and blue channel of color MRI, which are then entered into random subspace classifier for classification. The results have been compared with the state of art techniques and the proposed algorithm has been proved to be very simple and efficient with an accuracy of 98.64%.
KEYWORDS: Preprocessing, feature extraction, color moments, random subspace, MRI classification

1 INTRODUCTION

For the diagnosis of different diseases, there are many imaging modalities in medical sciences. Each modality has its own advantages and shortcomings. An imaging modality can be considered as a better one if it has high spatial resolution and discrimination capability among different tissues. Magnetic Resonance Imaging (MRI) is accepted as a better imaging modality by pathologists because it possesses both of these qualities. The accurate description of the anatomical structure of the brain by MRI enables the experts to measure the diseases quantitatively and carry out research in the field of medicine [1].

Since, the MRI provides rich information about the soft tissues of brain; the quality of diagnosis and treatment of brain diseases have been significantly improved [2]. Some functional modalities like Positron Emission Tomography (PET) has also got much benefit from brain MRI's rich information [3]. The experienced radiologists perform a complex procedure to characterize various diseases present in the soft tissues of the brain. Radiologists perform assessment of different features of MRI quite accurately and precisely. Nevertheless, different imaging techniques are continuously being investigated by medical experts for pathological characterization of the soft tissues of the brain for bringing more accuracy and effectiveness in the diagnosis and treatment of brain abnormalities [4].

For the examination of the human brain to find any disease in it, the primary source used by radiologists is the visual interpretation of the film. Almost all major functions of the human body, like blood pressure, temperature; memory and emotions, heart beat and fluid balance have direct communication with the human brain [5]. To ensure the normal functions of whole human body activities, the brain MRI classification into normal or abnormal is therefore important. In order to study human brain anatomy, many images are acquired to compare and determine differences between different human brains [6], [7]. For example, for comparison of the healthy brain, 176 images were used in [8], while for studying pediatric brains, 500 brain images were used by [9].

With the increase in number of objects, more accuracy has been observed in manual inspection. However, the manual inspection has some limitations such as it does not have the property of reproducibility and inspection required long computation time. The manual inspection of brain MRI is very cost expensive and there is a great shortage of experts in the field of radiology. Therefore, the automatic analysis, diagnosis, treatment and classification of medical images are becoming more and more important with the passage of time.For addressing all these and many other issues, many automatic algorithms have been proposed and developed over the last couple of

***Corresponding author:** Fazli Wahid, Universiti Tun Hussein Onn Malaysia. Email: wahid_uomian@hotmail.com
Tel: 00923459391200

years [10-13]. The standard methodology for brain MRI consists of four stages namely pre-processing, feature extraction, feature reduction and classification.

Pre-Processing: For bringing improvement in the quality of the image or making the image more suitable according to some requirements, some operations are performed on the images before actual processing. This is the preprocessing stage of image processing, which brings simplicity, speed and easiness in the further processing of the images. During the MRI preprocessing, the skull from the whole MRI is removed and the quality of MRI is improved by removing noise from it [14]. During skull removal, all those parts are removed from MRI, which are not part of the brain e.g. the skull itself, air and some other parts. All those pixels are removed from the actual MRI that represents these parts [15]. If real world MRI images are used for processing, then there are many standard methods for the removal of the skull. But, in order to make the process faster and easier for the researchers, some standard databases are available with the skull already removed from them, like, Internet Brain Segmentation Repository (IBSR) [16]. After, skull removal, noise is removed from MRI for which different types of filters are used e.g. fuzzy filter was used in [17] for removal of noise.

Feature extraction: Significant features for classification are identified and extracted during this stage. Since, the processing of the whole image is very time consuming, and a computationally complex task, some important characteristics that could describe the whole image without loss of any valuable information are extracted during this stage for the recognition of different patterns inside the images and their classification. These features should be so informative that they can represent the whole image, retaining the most relevant characteristics. From extracted features, a feature vector is then formed, which are used as inputs to the classifier for classification. Different types of features have been used in literature. As [18] and [19] used texture features and [17] used the threshold for brain MRI segmentation. Continuous Wavelet Transform (CWT) was used by [20] for brain MRI segmentation whereas [21] and [22] used Fractal Dimension (FD) texture features for brain MRI segmentation. In order to discriminate metastatic from primary brain tumors (gliomas and meningioma), [23] used textual features. The authors in [24], [25] and [26] used DWT (Discrete Wavelet Transform) for the classification of brain MRI.

Feature reduction: One of the most important problems of image processing applications is to cope with position, scaling and a large number of features. The large number of features extracted during the feature extraction stage increases computational time and speed dramatically. Therefore, these features need to be reduced to address the speed and complexity of processing. This technique for reducing the features is known as feature reduction or dimensionality reduction. A large number of feature reduction algorithms are available in literature, but the most important of them are PCA (Principal Component Analysis), LDA (Linear Discriminate Analysis) and ICA (Independent Component Analysis). Among these methods, PCA has been considered as the most widely used technique due to its efficiency, therefore, used by authors in [27] for feature reduction.

Classification: The division of MRI images into different classes is called classification. Two types of techniques, namely, supervised and unsupervised techniques are used for this purpose. Examples of supervised techniques are k-Nearest Neighbors (KNN) and the Artificial Neural Network (ANN) whereas examples of unsupervised techniques are fuzzy c-means and Self-Organizations Map (SOM) [28].

2 PROPOSED METHODOLOGY

In the proposed model, the classification of brain MRI into either normal or abnormal is accomplished in three stages i.e. pre-processing, feature extraction and classification.

In the MRI preprocessing, the median filter has been applied to remove salt and pepper noise from the MRI, which badly affects the quality of MRI images. Since the proposed algorithm uses color moments as main features for brain MRI classification, therefore, the grey scale MRI is converted into color MRI during this stage as well. Color moments have been considered as main features for classification of brain MRI. In order to extract color moments from an image, the image needs to be in color image format. There are many color image formats, but in our work, the grey scale MRI has been converted into the RGB image to extract the features efficient for description of the MRI.

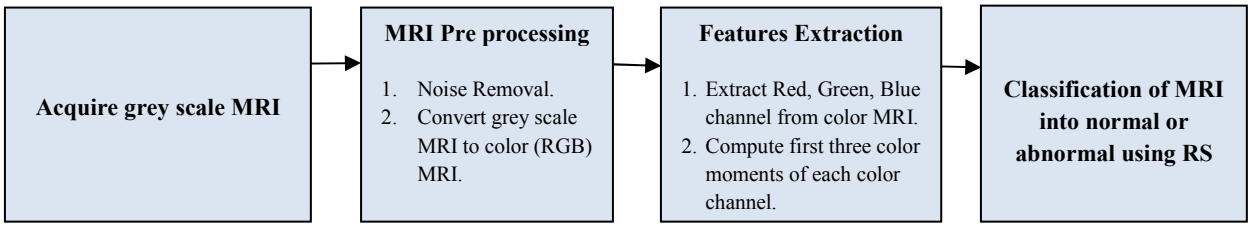

Figure 1: The Proposed Model

2.1 MRI Pre-Processing

After the acquisition of MRI images, the preprocessing step is performed for the removal of noise and cleaning-up the background of the image. Some undesired structures e.g. skull and scalp are also removed at this stage. In the proposed algorithm, following activities are performed during preprocessing

2.1.1 Noise removal
2.1.2 Skull removal
2.1.3 MRI transformation

2.1.1 Noise removal

At this stage, the median filter of size 3x3 has been used for the removal of noise. This type of filter has been used because it is an efficient filter for removal of salt and pepper noise, which is the main type of noise affecting the brain MRI. The median filter is also considered as the efficient filter for removal of noise without disturbing the edges of the image.

2.1.2 Skull removal

During this stage, all those parts are removed from the brain MRIs that are not the parts of the brain. Many techniques are available for skull removal if some real images are considered for classification. There are many standard data sets available having the skull already removed, for the easiness of researchers. In the proposed algorithm, images have been downloaded from the Harvard Medical College website with the skull already removed from them.

2.1.3 MRI transformation

Since, we use color moments as our main features for the description of MRI, the grey scale images need to be converted into color (RGB). We will extract three color channels, namely, the red, green and blue channel from our RGB image to extract color features from them. Figure 2 (a) shows the grey scale image whereas figure 2 (b)shows the color (RGB) image after transformation.

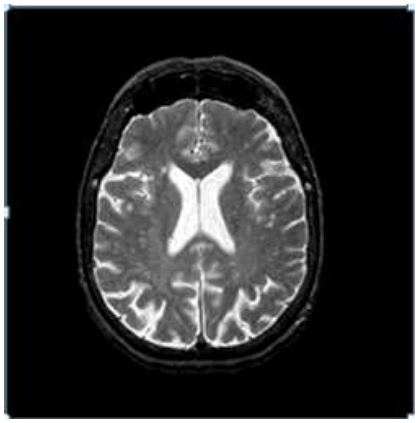

Figure 2: (a) Grey scale MRI image before pre-processing

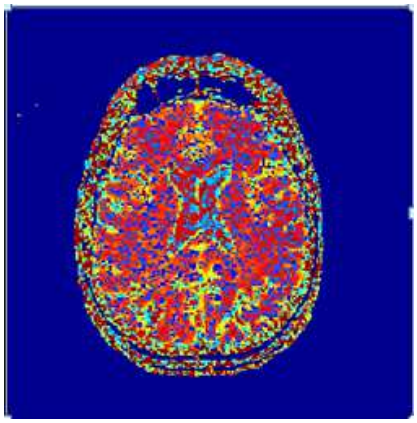

Figure 2:(b) Colored RGB MRI after pre-processing

2.2 Features extraction

In the proposed algorithm, color moments of red, green and blue channels have been used as main features for the description of MRI images. In order to extract color moments, the grey scale MRI is needed to be converted into the color (RGB) image, and then first three color moments are extracted from each channel. The description of each color moment is given in the following section.

2.2.1 Mean

Mean is the first color moment, representing the average of all pixels' intensities of each color channel.

2.2.2 Variance

Variance is the second color moment, representing variations in distributions of intensities in each color channel

2.2.3 Skewness

Skewness is the third color channel representing the asymmetry of color distribution in each channel.

2.2.4 Mathematical representation of Color Moments

For the extraction of features, the brain MRI image has been converted into color MRI and from the color MRI, three channels namely red, green and blue channels have been extracted. From each color channel, three moments (means) have been computed. So, a total of nine features (three from each color channel) have been extracted as main features. All these features are represented by following mathematical equations.

$$M_{1,1} = \frac{1}{N}\sum_{J=1}^{N} I_j \quad (1)$$

$$M_{1,2} = \frac{1}{N}\sum_{j=1}^{N}\left(I_j - M_{1,1}\right)^2 \quad (2)$$

$$M_{1,3} = \frac{1}{N}\sum_{1}^{N}\left(I_j - M_{1,1}\right)^3 \quad (3)$$

$$M_{2,1} = \frac{1}{N}\sum_{J=1}^{N} I_j \quad (4)$$

$$M_{2,2} = \frac{1}{N}\sum_{j=1}^{N}\left(I_j - M_{2,1}\right)^2 \quad (5)$$

$$M_{2,3} = \frac{1}{N}\sum_{1}^{N}\left(I_j - M_{2,1}\right)^3 \quad (6)$$

$$M_{3,1} = \frac{1}{N}\sum_{J=1}^{N} I_j \quad (7)$$

$$M_{3,2} = \frac{1}{N}\sum_{j=1}^{N}\left(I_j - M_{3,1}\right)^2 \quad (8)$$

$$M_{3,3} = \frac{1}{N}\sum_{1}^{N}\left(I_j - M_{3,1}\right)^3 \quad (9)$$

Where $M_{1,1}$, $M_{1,2}$, $M_{1,3}$represents mean, variance and skewness of the red color channel, respectively. $M_{2,1}$, $M_{2,2}$, $M_{2,3}$ represents mean, variance and skewness of the green color channel, respectively. $M_{3,1}$, $M_{3,2}$, $M_{3,3}$ represents mean, variance and skewness of the blue color channel, respectively. I represent the intensity of each pixel in the red, green and blue channel and N represent the total number of pixels in the channels.

2.3 MRI Classification

For the classification of normal and abnormal brain MRI, random subspace classifier has been used, which uses K-Nearest Neighbors (KNN) as base classifier. The fact behind the successfulness of ensemble classification is the diversity in the classification that makes the ensemble classifier. In the ensemble classification method, every classifier gives different errors on different instances. Due to this fact, a strong classifier can be developed that can reduce the error.

Random subspace classifier is one of these machine learning classifiers, which divides the whole feature space into subspaces. Each subspace randomly chooses features from the original feature space. It must be ensured that the boundaries of the individual base classifier are significantly different. For this purpose, an instable or weaker classifier is used as base classifier because they generate adequately different decision boundaries even for small unrest in the training data parameters.

The majority voting method has been used for the final decision of the class membership. In the proposed algorithm, K-nearest neighbor has been used as base classifier due to its simple operations. After choosing a random subspace, a new set of K nearest neighbors is computed. The majority voting method has been used to combine the output of each base classifier for the decision making test class.

3 EXPERIMENTAL SETUP

All the experiments have been performed on Intel Core i5 with 4.00 GB of memory with the windows 7 operating system installed on it. For feature, extraction and pre-processing, MATLAB 7.6.0 (R2008a) was used whereas for classification purpose, Weka 3.7.10 was used. The proposed approach was tested on 200 T-2 weighted images downloaded from www.med.harvard.edu/AANLIB (Harvard Medical School Website). Out of these 200 images, 100 images were normal images whereas 100 were abnormal images.

3.1Algorithm Accuracy

The total data set was divided into 70% training and 30% testing data set. The algorithm gave 98.46% accuracy for testing data set. The experimental results are shown in the following tables. For making the algorithm more generalized, cross validation was applied, which gave 92.85% accurate results. The experimental results are shown in the following tables

3.2 Comparative Analysis

In this subsection, the results of the proposed architecture have been compared with the state of art techniques.

Table 1. Comparison of the proposed technique with other classifiers

Serial No	Classifier	Results
1	Normal densities based linear classifier	73.08% Accuracy
2	Naive Bayes Classifier	76.92% Accuracy
3	Support vector classifier	88.46% Accuracy
4	Artificial Neural Network	91.80% Accuracy
5	Random Subspace (Proposed Algorithm)	98.46 % Accuracy

Table 1 shows the comparison of random subspace classifier with other famous classifiers, namely Normal Densities based Linear Classifier, Support Vector Machine, Naïve Bayes classifier and Artificial Neural Network. The random subspace ensemble classifier outperforms these famous single classifiers.

Table 2. Classification results for discrimination of primary and secondary tumors using LOO method [23]

Technique Used	Primary Brain Tumor Accuracy	Secondary Brain Tumor Accuracy	Overall Accuracy
PNN	86.96	95.24	89.55
Linear LSFT-PNN	89.13	95.24	91.04
SVM-RBF	91.30	85.71	89.55
Cubic LSFT-PNN	93.48	95.24	94.03
Proposed Approach	Normal MRI	Abnormal MRI	98.46

Table 3. Classification results for discrimination of primary and secondary tumors using ECV method [23]

Technique Used	Primary Brain Tumor Accuracy	Secondary Brain Tumor Accuracy	Overall Accuracy
PNN	84.38	52.86	74.78
Linear LSFT-PNN	89.38	37.14	73.48
SVM-RBF	93.75	30.00	74.35
ANN	88.13	61.43	80.00
Cubic LSFT-PNN	81.25	71.43	78.26
Proposed Approach	Normal MRI	Abnormal MRI	98.46

Table 2 and Table 3 show the comparison of the proposed technique with the leave one out (LOO) method and external cross validation (ECV) methods applied by the authors in [23]. The authors have applied different techniques for discrimination of the primary and secondary brain tumor. The proposed technique gives better results than all the techniques described by the authors in [23].

Table 4. Results comparison with some other classification techniques with respect to accuracy

Technique	Classification	Accuracy
Hierarchical ascending classification [29]	Tumor VS Edemas	49%
Hierarchical ascending classification [29]	Benign VS malignant	63%
Discriminant analysis and KNN [4]	Tumor VS Edemas	95%
DWT + SOM [25]	Normal VS Abnormal	94%
DWT + SVM [25]	Normal VS Abnormal	98%
DWT + FP-ANN [30]	Normal VS Abnormal	97%
DWT + KNN [30]	Normal VS Abnormal	98%
LSFT + PNN [23]	Metastatic VS Primary Tumor	95.24%
LSFT + PNN [23]	Gliomas VS Meningioma's	93.48 %
Random Subspace (Proposed Algorithm)	Normal VS Abnormal	98.46%

Table 4 shows the comparison of the proposed technique with some other classification techniques presented by the different authors for binary classification and the results obtained from the proposed technique is better than described techniques.

Table 5. Results comparison with some other classification techniques with respect to complexity and number of features used

Technique	Number of features	Accuracy
DWT + SOM [25]	4761	94.00%
DWT + SVM with linear kernel [25]	4761	96.15%
DWT + SVM with polynomial kernel [25]	4761	98.00%
DWT + SVM with radial basis function based kernel [25]	4761	98.00%
Random Subspace (Proposed Algorithm)	9	98.46%

Table 5 shows the comparison of the proposed technique with SOM and SVM with different types of kernels. The proposed technique outperforms all these methods in terms of the number of features and the accuracies reported by these authors. The proposed technique uses fewer features as compared to the techniques presented in Table 5 and also gives better results.

4 DISCUSSION

After comparison of the proposed technique with the techniques presented in Table 1, Table 2, Table 3, Table 4 and Table 5, a conclusion can be drawn that the proposed algorithm performs better than all these techniques in terms of complexity and accuracy. The architecture of the proposed algorithm is simpler than all these techniques and provides better results as well. Almost all techniques shown in the tables use more features than the proposed architecture due to the fact the color features are more informative features than other features and therefore provide better description of the images. All algorithms have used some feature reduction algorithm to reduce the features whereas in our algorithm; this step has been eliminated, which reduces computational complexity to a large extent. The classifier used in our proposed architecture is also simpler and efficient than classifiers used by authors of above algorithms. The major advantages associated with this new approach is that it can be extended to other types of classification problems e.g. gender classification with keeping in considerations the facts explored in this proposed work.

5 CONCLUSION AND FUTURE WORK

In order to discriminate between the normal and pathological brain MRI, we have applied a machine learning technique in combination with the useful color features of the brain MRI images. In this paper, a new approach has been presented for extraction of useful features from the brain MRI images which are then used as input to the random subspace classifier. From experimentation, it is evident that random subspace provides higher prediction accuracy as compared to many existing classifiers as mentioned in result comparison. In the proposed work, a very simple procedure has been used for brain MRI classification. In this work, the results obtained are not hundred percent correct, but in future work, it will be tried to get 100% accurate results by combining some other useful features with current features and also a hybrid model will be developed to achieve more accuracy.

REFERENCES

[1] Shenton, M. E., Kikinis, R., Jolesz, F. A., Pollak, S. D., LeMay, M., Wible, C. G., &McCarley, R. W, 1992. Abnormalities of the left temporal lobe and thought disorder in schizophrenia: a quantitative magnetic resonance imaging study. New England Journal of Medicine, 327(9), 604-612.

[2] Fletcher-Heath, L. M., Hall, L. O., Goldgof, D. B., &Murtagh, F. R, 2001. Automatic segmentation of non-enhancing brain tumors in magnetic resonance images. Artificial intelligence in medicine, 21(1), 43-63.

[3] Levin, D. N., Hu, X. P., Tan, K. K., Galhotra, S., Pelizzari, C. A., Chen, G. T., &Mullan, J. F. 1989. The brain: integrated three-dimensional display of MR and PET images. Radiology, 172(3), 783-789.

[4] Lerski, R. A., Straughan, K., Schad, L. R., Boyce, D., Blüml, S., &Zuna, I, 1993. VIII. MR image texture analysis—an approach to tissue characterization. Magnetic resonance imaging, 11(6), 873-887.

[5] Fayaz, M., Shah, A. S., Wahid, F.,&Shah, A, 2016. A Robust Technique of Brain MRI Classification using Color Features and K-Nearest Neighbors Algorithm. International Journal of Signal Processing, Image Processing and Pattern Recognition, 9 (10), 11-20.

[6] Wahid. F., Fayaz.M., and Shah. A.S., 2016.An Evaluation of Automated Tumor Detection Techniques of Brain Magnetic Resonance Imaging (MRI). International Journal of Bio-Science and Bio-Technology, 8(2),265-278.

[7] Nazir. M., Wahid. F. and Khan. S. A., 2015.A Simple and Intelligent Approach for Brain MRI Classification. Journal of Intelligent & Fuzzy Systems: Applications in Engineering and Technology, 28(3), 1127-1135.

[8] Sowell, E. R., Peterson, B. S., Thompson, P. M., Welcome, S. E., Henkenius, A. L., & Toga, A. W, 2003. Mapping cortical change across the human life span. Nature neuroscience, 6(3), 309-315.

[9] Evans, A. C., & Brain Development Cooperative Group, 2006. The NIH MRI study of normal brain development. Neuroimage, 30(1), 184-202.

[10] Cocosco, C. A., Zijdenbos, A. P., & Evans, A. C, 2003. A fully automatic and robust brain MRI tissue classification method. Medical image analysis,7(4), 513-527.

[11] Kim, J. S., Singh, V., Lee, J. K., Lerch, J., Ad-Dab'bagh, Y., MacDonald, D., & Evans, A. C, 2005. Automated 3-D extraction and evaluation of the inner and outer cortical surfaces using a Laplacian map and partial volume effect classification. Neuroimage, 27(1), 210-221.

[12] Tohka, J., Zijdenbos, A., & Evans, A, 2004. Fast and robust parameter estimation for statistical partial volume models in brain MRI. Neuroimage,23(1), 84-97.

[13] Singh, V. 2005. Use of a non-stationary markov random field in brain tissue partial volume segmentation.

[14] Shanthi, K. J., Sasikumar, M. N., &Kesavadas, C, 2010. Neuro-fuzzy approach toward segmentation of brain MRI based on intensity and spatial distribution. Journal of Medical Imaging and Radiation Sciences, 41(2), 66-71.

[15] Węgliński, T., &Fabijańska, A, 2011. Brain tumor segmentation from MRI data sets using region growing approach. In Perspective Technologies and Methods in MEMS Design (MEMSTECH), 2011 Proceedings of VIIth International Conference on (pp. 185-188). IEEE.

[16] Ortiz, A., Górriz, J. M., Ramírez, J., Salas-Gonzalez, D., & Llamas-Elvira, J. M, 2013. Two fully-unsupervised methods for MR brain image segmentation using SOM-based strategies. Applied Soft Computing, 13(5), 2668-2682.

[17] Zarandi, M. F., Zarinbal, M., &Izadi, M, 2011. Systematic image processing for diagnosing brain tumors: A Type-II fuzzy expert system approach. Applied soft computing, 11(1), 285-294.

[18] Haralick, R. M., &Shanmugam, K, 1973. Textural features for image classification. IEEE Transactions on systems, man, and cybernetics, (6), 610-621.

[19] Khan. H. K., Shah.A.S., and Khan.M. A., 2016. Critical Evaluation of Frontal Image-Based Gender Classification Techniques. International Journal of Signal Processing, Image Processing and Pattern Recognition, 9(10).

[20] Iscan, Z., Dokur, Z., &Ölmez, T, 2010. Tumor detection by using Zernike moments on segmented magnetic resonance brain images. Expert Systems with Applications, 37(3), 2540-2549.

[21] Iftekharuddin, K. M., Zheng, J., Islam, M. A., &Ogg, R. J, 2009. Fractal-based brain tumor detection in multimodal MRI. Applied Mathematics and Computation, 207(1), 23-41.

[22] Iftekharuddin, K. M., Jia, W., & Marsh, R, 2003. Fractal analysis of tumor in brain MR images. Machine Vision and Applications, 13(5-6), 352-362.

[23] Georgiadis, P., Cavouras, D., Kalatzis, I., Daskalakis, A., Kagadis, G. C., Sifaki, K. &Solomou, E, 2008. Improving brain tumor characterization on MRI by probabilistic neural networks and non-linear transformation of textural features. Computer methods and programs in biomedicine, 89(1), 24-32.

[24] Arizmendi, C., Vellido, A., & Romero, E, 2012. Classification of human brain tumours from MRS data using Discrete Wavelet Transform and Bayesian Neural Networks. Expert Systems with Applications, 39(5), 5223-5232.

[25] Maitra, M., &Chatterjee, A, 2006. A Slantlet transform based intelligent system for magnetic resonance brain image classification. Biomedical Signal Processing and Control, 1(4), 299-306.

[26] Georgiadis, P., Cavouras, D., Kalatzis, I., Glotsos, D., Athanasiadis, E., Kostopoulos, S., &Solomou, E, 2009. Enhancing the discrimination accuracy between metastases, gliomas and meningiomas on brain MRI by volumetric textural features and ensemble pattern recognition methods. Magnetic resonance imaging, 27(1), 120-130.

[27] Latifoğlu, F., Polat, K., Kara, S., &Güneş, S, 2008. Medical diagnosis of atherosclerosis from Carotid Artery Doppler Signals using principal component analysis (PCA), k-NN based weighting pre-processing and Artificial Immune Recognition System (AIRS). Journal of Biomedical Informatics, 41(1), 15-23.

[28] Chaplot, S., Patnaik, L. M., &Jagannathan, N. R, 2006. Classification of magnetic resonance brain images using wavelets as input to support vector machine and neural network. Biomedical Signal Processing and Control, 1(1), 86-92.

[29] Herlidou-Meme, S., Constans, J. M., Carsin, B., Olivie, D., Eliat, P. A., Nadal-Desbarats, L., & De Certaines, J. D, 2003. MRI texture analysis on texture test objects, normal brain and intracranial tumors. Magnetic resonance imaging, 21(9), 989-993.

[30] El-Dahshan, E. S. A., Hosny, T., & Salem, A. B. M, 2010. Hybrid intelligent techniques for MRI brain images classification. Digital Signal Processing,20(2), 433-441.